

# Silver dressing use in chronic wounds: Let clinical judgment be the guide

**Annemarie Brown**

*Annemarie Brown is Consultant Nurse—Tissue Viability, Mid Essex Hospitals NHS Trust*

*Email: Annemarie.Brown2@meht.nhs.uk*

Wound healing is a complex process involving the interaction of many different cells, matrix components and biological factors – including growth factors, proteinases and cytokines – in a fluid environment (Baker and Leaper, 2000). Achieving a therapeutic balance of moisture levels in a wound is a challenge for clinicians, particularly when little is known about what constitutes the correct amount required for successful wound healing (Bishop et al, 2003).

In 1962 Winter demonstrated that moisture is beneficial in wound healing, but that excess moisture can lead to excoriation, maceration and further wound complications (Vowden and Vowden, 2003). Winter's theory however, focused on acute wounds, and in the absence of more definitive guidance, clinicians must assume that the same principles of moisture balance also apply to chronic wounds. What is known, however, is that it is not merely the amount of exudate that is detrimental to wound healing, but more specifically, the nature of the fluid (Bishop et al, 2003). It has been suggested that the content and nature of wound fluid reflects the wound status and can be used to predict if a wound is likely to proceed to healing (Staiano-Coico et al, 2000). Many factors influence the quantity and consistency of

exudate production, in particular, the presence of wound infection.

## Wound infection

Wound infection has a significant financial impact on NHS resources as well as on patient quality of life. Collier (2004) has suggested that the incidence of hospital-acquired infection related to surgical wounds is as high as 10%. These infections complicate illness, cause anxiety, increase patient discomfort and can lead to death. The cost to the NHS is estimated at almost £1 billion per annum (Nosocomial Infection National Surveillance Service, 2002).

From the patient's perspective, a wound infection is associated with increased levels of pain, and may involve living with a highly exuding, and potentially malodorous wound. If the patient is of working age, this may result in lost income and further expenditure in expensive prescription charges. Infection in acute or surgical wounds in otherwise healthy patients is usually obvious (World Union of Wound Healing Societies (WUWHS), 2008) and can be diagnosed using the triggers for suspecting acute wound infection detailed in *Table 1*.

Infection is a common problem in chronic wounds, frequently resulting in non-healing and significant patient morbidity and mortality (Siddiqui and Bernstein, 2010). However, in chronic wounds and with debilitated patients, diagnosis may rely on the recognition of subtle local signs or non-specific general signs, such as loss of appetite, malaise or deterioration of glycaemic control in diabetic patients (WUWHS, 2008). Clinical signs of chronic wound infection are outlined in *Table 2*.

## Infection development

To identify and manage wound infection correctly, it is necessary to understand how wound infection develops. This process has been described as occurring on a continuum (Kingsley, 2003), which describes the interaction between the bacteria in the wound and the patient's immune response. The significance of bacteria in wounds presents a continuum from contamination through colonization to critical colonization and, finally, to infection (*Figure 1*) (Kingsley, 2003). Even though it is virtually inevitable that most wounds will contain microorganisms, many go on to heal uneventfully. However, sometimes bacteria within the

## ABSTRACT

Recent literature has suggested that silver dressings may be ineffective in treating infected or critically colonized wounds. This article discusses the development of chronic wound infection and appropriate clinical management. The role of exudate and how wound infection can impact on exudate production is discussed, together with the impact on patients' quality of life. The history and development of silver as a treatment for wound infection is described, as well as its mode of action. The current evidence base on the efficacy of silver is briefly discussed, together with implications for clinical practice. In the absence of irrefutable evidence that silver is ineffective in the treatment of infected chronic wounds, clinicians are encouraged to use their clinical judgment when selecting products to manage wound infection. Atrauman® Ag is introduced as an effective, versatile and competitively priced dressing for use in the treatment of infected or critically colonized wounds, and its effective use is illustrated with case studies.

## KEY WORDS

♦ Silver dressings ♦ Chronic wounds ♦ Colonized and infected wounds

**Table 1. Clinical signs of acute wound infection**

Localized infection	Spreading infection
<ul style="list-style-type: none"> <li>• Classical signs and symptoms:                             <ul style="list-style-type: none"> <li>– New or increasing pain</li> <li>– Erythema</li> <li>– Local warmth</li> <li>– Swelling</li> <li>– Purulent discharge</li> </ul> </li> <li>• Pyrexia: typically 5–7 days post-surgery in surgical wounds</li> <li>• Delayed/stalled healing</li> <li>• Abscess</li> <li>• Malodour</li> </ul>	<ul style="list-style-type: none"> <li>• As for localized infection PLUS:                             <ul style="list-style-type: none"> <li>– Further extension of erythema</li> <li>– Lymphangitis</li> <li>– Crepitus in soft tissues</li> <li>– Wound breakdown/dehiscence</li> </ul> </li> </ul>

*Adapted from: Cutting and Harding (1994); Gardner et al (2001); European Wound Management Association (2005)*

wound multiply, invade and damage tissue, delaying healing and occasionally causing systemic illness (WUWHS, 2008). Using the continuum, contamination is defined by WUWHS (2008) as:

*‘bacteria within a wound which do not increase in number or cause clinical problems’.*

### Colonization

Colonization may enhance or impede healing, depending on the bacterial load in the wound. Bacterial loads in excess of 10<sup>5</sup> organisms/gram of tissue are considered to impede healing; although this threshold may be altered by the health status of the patient and the type of bacteria present (Siddiqui and Bernstein, 2010). The term critical colonization is controversial and not universally accepted

as the term needs more definitive clarification (Siddiqui and Bernstein, 2010). However, it has been described as a state of increased bacterial burden or covert infection resulting in a wound which enters a non-healing, chronic inflammatory state. The signs of critical colonization – which are commonly seen in clinical practice – are:

- ♦ Atrophy/deterioration of granulation tissue
- ♦ Colour change of granulation tissue to deep red or grey
- ♦ Increased wound friability
- ♦ Increased exudate (Frank et al, 2005).

The following case studies presented within this article discuss wounds which were treated with Atrauman® Ag. Case study 1 describes the management of a wound which was critically colonized.

### Case study 1

This was a 78 year old gentleman who was admitted with a chronic Grade 3 pressure ulcer to his right heel (Figure 2). On initial assessment, the wound measured 8.5 x 7 cm. The wound bed consisted of 70% slough, 10% necrotic tissue and 20% pale granulation tissue. The surrounding skin was macerated and the wound was exuding heavily. These signs, together with increasing cellulitis, oedema and malodour suggested that the wound was critically colonized. Atrauman® Ag was applied, together with a foam dressing. After 4 weeks, the wound measured 7 x 6.9 cm, representing a 13.75% reduction in size, the exudate had decreased significantly and the slough and necrotic tissue had almost disappeared. The Atrauman® Ag was then discontinued.

### Transition to infection

The transition to infection occurs when the multiplying bacteria overcome the patient’s immune response and can

**Table 2. Clinical signs of chronic wound\* infection**

Localized infection	Spreading infection
<ul style="list-style-type: none"> <li>• New, increased or altered pain<sup>†</sup></li> <li>• Delayed or stalled healing<sup>†</sup></li> <li>• Peri-wound oedema</li> <li>• Bleeding or easily damaged granulation tissue</li> <li>• Distinctive malodour or change in odour</li> <li>• Wound bed discolouration</li> <li>• Increased or altered/purulent exudate</li> <li>• Induration</li> <li>• Pocketing</li> <li>• Bridging</li> </ul>	<ul style="list-style-type: none"> <li>As for localized infection PLUS:                             <ul style="list-style-type: none"> <li>• Wound breakdown<sup>†</sup></li> <li>• Erythema extending from wound edge</li> <li>• Crepitus, warmth, induration and discolouration spreading into peri-wound area</li> <li>• Lymphangitis</li> <li>• Malaise or other non-specific deterioration in patient’s general condition</li> </ul> </li> </ul>

#### Notes

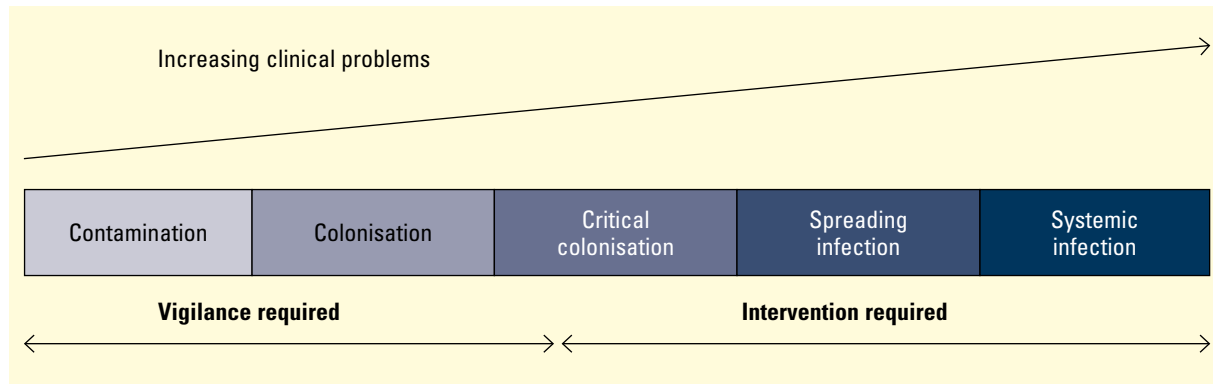
- In patients who are immunocompromised and/or who have motor or sensory neuropathies, symptoms may be modified and less obvious. For example, in a diabetic patient with an infected foot ulcer and peripheral neuropathy, pain may not be a prominent feature
- In the case of arterial ulcers, previously dry ulcers become wet when infected
- Clinicians should be aware that in the diabetic foot, inflammation is not necessarily indicative of infections. For example, inflammation may be associated with Charcot’s arthropathy.

\*Chronic wounds include diabetic foot ulcers, venous leg ulcers, arterial leg/foot ulcers and pressure ulcers

<sup>†</sup> Individually highly indicative of infection. Infection is also highly likely in the presence of two or more of the other signs listed

Adapted from: Cutting and Harding 1994; Gardner et al, 2001; European Wound Management Association, 2005)

Figure 1. Wound infection continuum (Kingsley, 2003)



no longer be contained. Several factors determine the transition from colonization to infection: the bacterial burden itself, the virulence of the organism – particularly when two or more bacteria types unite in the wound – and the strength of the patient’s immune system. Diabetes, malnutrition, long-term steroid use, obesity and advanced age will all increase the risk of progression from colonization to infection, as will poor tissue perfusion, necrotic tissue, foreign bodies, undermining and tunnelling of the wound (Bowler and Davies, 1999).

**Implications for practice**

Wound infection in acute wounds is generally treated with systemic antibiotics once the bacteria responsible have been identified following wound swab culture (Bowler et al, 2001). Treating wound infection in chronic wounds, however, is not as straightforward. The clinical identification of local infection in chronic wounds can be challenging because of the frequent absence of the typical signs of infection. Redness, heat, pain, swelling and exudate may be minimal or absent as a result of factors which commonly contribute to the formation of chronic wounds. Advanced patient age, poor tissue perfusion, poor oxygenation, immunocompromised state, diabetes and the use of anti-inflammatory drugs can dampen the patient’s immune response, which would normally produce the typical signs of inflammation and infection (Collier, 2004). This can be clearly observed in the following case study.

**Case study 2**

This was a 47 year old gentleman who had Type 1 diabetes. He was a builder by trade and had developed the wound to his foot by wearing incorrect footwear (Figure 3). As he had peripheral neuropathy, he only became aware of the wound when an unpleasant odour had developed. On initial assessment, the wound measured 5 x 3 cm and the wound bed consisted of 70% slough and 30% granulation tissue. The skin surrounding the wound was healthy and intact; however, the wound was producing heavy, purulent exudate. Infection by Methicillin-resistant *Staphylococcus aureus* was confirmed by wound swab. Atrauman® Ag together with a foam dressing was used for 20 days. After

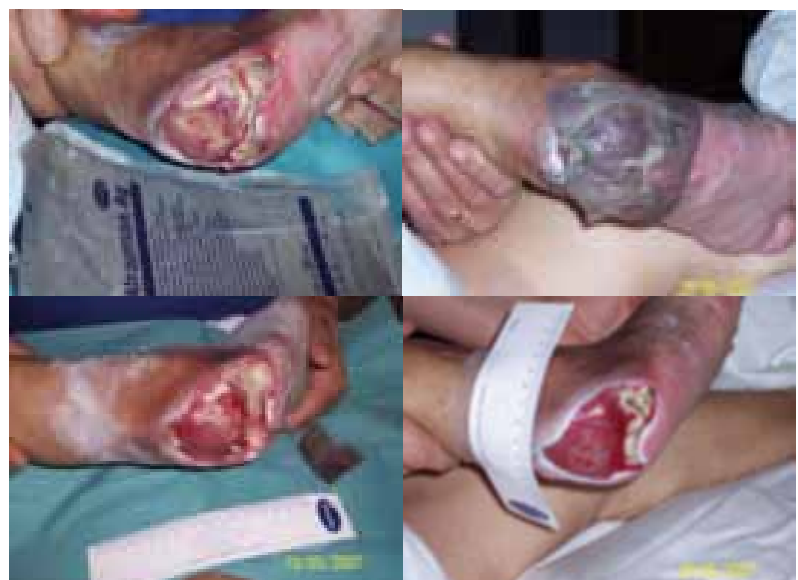

Figure 2. Case study 1

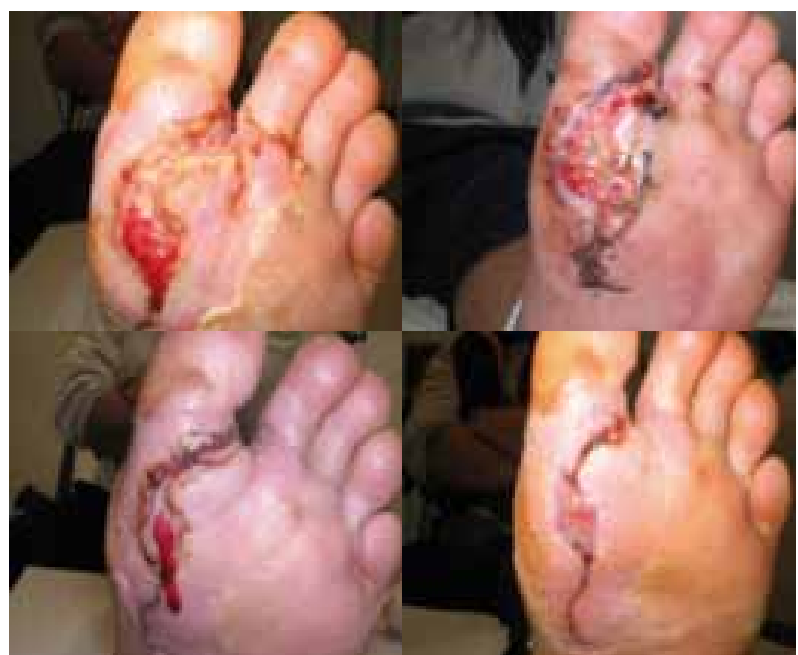

Figure 3. Case study 2

this time, the infection had cleared and the wound bed consisted of 100% granulation tissue, the level of exudate had reduced and the wound dimensions were 3 x 0.5 cm, representing 90% reduction in wound area.

### Chronic wounds

Chronic wounds have a complex colonizing flora which changes over time, and the longer a wound remains unhealed, the more likely it is that the wound will acquire multiple organisms, both aerobic and anaerobic (Siddiqui and Bernstein, 2010). Intervention is usually only required when the patient is at high risk of wound infection or when the interaction between the bacteria in the wound and the patient's immune defence impairs healing, causes deterioration of the wound and results in localized, spreading or systemic infection (WUWHS, 2008).

When assessing chronic wounds for infection, clinicians must be mindful of the individual patient and consider their immune response, comorbidities, wound aetiology and status before taking a wound swab for microbiological analysis. Wound swabbing should be reserved only:

- ◆ For acute wounds with signs of infection
- ◆ For chronic wounds which exhibit signs of spreading or systemic infection
- ◆ For chronic wounds which have not responded to or are deteriorating despite topical antimicrobial treatments
- ◆ According to local protocol.

It has been suggested that routine swabbing, such as at weekly intervals or at the time of frequent dressing changes, is neither helpful nor cost effective, and has been estimated to cost between £15-£25 per swab (Collier, 2004). When a chronic wound infection is suspected, the focus of interventions should be on:

- ◆ Enhancing the patient's ability to fight infection and improve their healing potential by addressing potential systemic factors that may have contributed to the wound infection, e.g. diabetic glycaemic control and the use of disease-modifying drugs in rheumatoid arthritis (WUWHS, 2008)

- ◆ Reducing the bacterial load in the wound and optimizing the wound bed by strict infection control measures, and debridement of necrotic tissue by sharp/surgical means or by use of dressings to facilitate autolytic debridement
- ◆ Increased dressing changes if required, wound cleansing at every dressing change, and management of exudate and malodour
- ◆ Use of topical antiseptics for local infection, and possible use of systemic antibiotics if no improvement after 10-14 days or if there is evidence of deterioration or spreading infection (WUWHS, 2008).

### Managing exudate in wound infection

An increase in or excessive exudate can be a sign of increasing levels of bacterial colonization, which may lead to wound infection (Adderley, 2010). In addition, there may be a change in consistency of exudate as the increased protein levels make it more 'sticky', thick and malodorous (Thompson and Stephen-Haynes, 2007; Adderley, 2010). An example of this would be the presence of *Pseudomonas aeruginosa* in a wound, which renders the exudate thick and greenish-blue in colour, together with a very distinctive odour (Cooper and Lawrence, 1996), as described in the following case study.

#### Case study 3

This was a 57 year old who developed venous leg ulcers following an acute episode of cellulitis (Figure 4). He had a history of chronic cellulitis and on examination had evidence of lipodermatosclerosis. The ulcers were superficial but exuding thick green exudate which was malodorous. The wounds were not swabbed as the clinical signs suggested the presence of *P. aeruginosa*. Atrauman<sup>®</sup> Ag was applied for one week, with Zetuvit as a secondary dressing. Once the exudate had reduced and the ulcers appeared clean, four-layer bandaging was applied to reduce oedema, manage exudate and promote healing of the leg ulcers.

### The role of exudate in the normal healing process

To understand how wound infection results in excessive exudate it is necessary to describe the role of exudate in the normal healing process. A consistent factor for all chronic wounds is a prolonged inflammatory response (Moore, 1999), with cells associated with the inflammatory phase present in the wound exudate (Buchan et al, 1980). Inflammation leads to an increase in vasodilatation and vessel permeability. In this way, there is continual additional extracellular fluid formation and this usually results in an increased and prolonged production of wound fluid and exudate (Vowden and Vowden, 2003). If a wound infection develops from colonization with pathogenic bacteria, the exudative

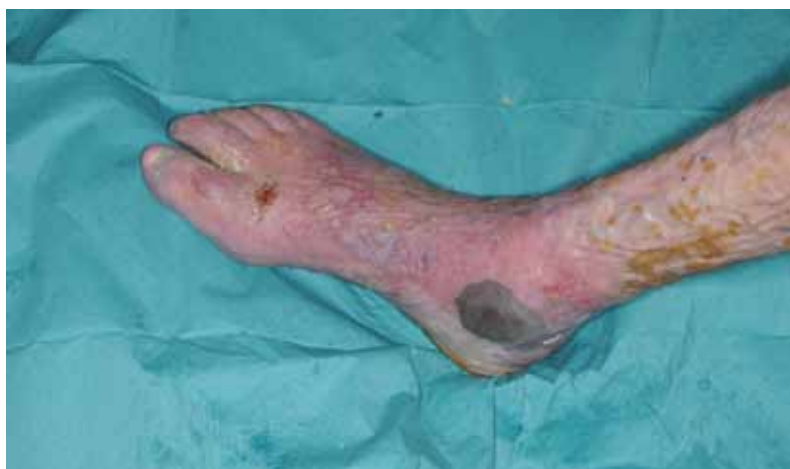

Figure 4. Case Study 3

healing phase is increased significantly so that the proliferative and regenerative phases are either delayed or do not happen at all (Kapp and Smola, 2005). Excessive exudate impacts significantly on the patient's quality of life, and if not managed effectively, will result in malodour and maceration to the peri-wound skin, wound deterioration and more pain for the patient.

## Topical antiseptics: The role of silver

Silver was used as a preservative by the ancient Greeks and Romans (Kapp and Smola, 2005), and its medicinal use became widespread in the 19th century. More recently it has been used in wound dressings and the development of silver-containing wound dressings has markedly improved the local management of critically colonized and infected wounds (Dunn and Edwards-Jones, 2004).

Unlike antibiotics that usually target only one cell function, silver interferes with microbial proliferation by altering DNA and RNA, which causes fatal structural changes in bacterial cell walls and membranes (Jorgensen et al, 2005; Bolton, 2006). Silver ions are released from the dressing into the wound fluid or exudate and act against a wide spectrum of pathogens such as aerobic, anaerobic, gram-negative and gram-positive bacteria, yeasts and viruses (Dunn and Edwards-Jones, 2004). These types of dressings are particularly advantageous in cases where systemic antibiotic treatment is not needed, but where local antimicrobial activity is desired (Ziegler et al, 2006). In addition, the long-lasting antimicrobial action and the significantly reduced risk of bacterial resistance associated with silver are considered an advantage in light of the widespread debate about when and how to initiate treatment in infected wounds, particularly wounds infected with antibiotic-resistant bacteria, such as *Staph. aureus* (Murphy et al, 1992). Unfortunately, released silver ions are cytotoxic to human cells (Poon and Burd, 2004) and there is an inherent problem balancing antimicrobial activity against cytotoxicity (Bowler et al, 2001). This can, however, be addressed by controlling silver release by varying the amount of available silver in the dressing, the surface area of the silver particles and the chemical composition of the silver preparation (Ziegler et al, 2006)..

## Efficacy of silver: The evidence

There are at least 40 different antimicrobial dressings listed in the latest Wound Care Handbook (MA Healthcare) (Michaels et al, 2009) and the use of these dressings has become widespread, particularly for venous leg ulcers. Concerns over inappropriate or over-use of silver products and the financial implications for the NHS – estimated at £25 million between 2006/7 (National Prescribing Centre (2008)) – have prompted several studies to establish the efficacy of silver in wound healing (O'Meara et al, 2001; Lo et al, 2008; Michaels et al, 2009; Vermeulen et al, 2009; Storm-Versloot et

al, 2010). The findings of these studies are somewhat contradictory. Vermeulen et al (2009) concluded that there was insufficient evidence to recommend the use of silver-containing dressings or topical agents for the treatment of infected or contaminated chronic wounds, owing to poor quality randomized controlled trials (RCTs). However, the authors acknowledged that exudate leakage was significantly less frequent in patients with venous leg ulcers and chronic wounds treated with a silver dressing. Lo et al (2008) concluded that silver dressings demonstrated an overall positive effect in the management of infected chronic wounds in terms of infection and inflammation control, tissue management, moisture balance and epithelial advancement. However, they caution that the studies reviewed had small sample sizes and allude to the difficulties of confounding variables when conducting RCTs in wound care. A study that has impacted significantly on the use of silver products is the VULCAN trial (Michaels et al, 2009), the results of which have discouraged practitioners from prescribing silver dressings. This RCT and cost-effectiveness analysis of silver-donating dressings for venous leg ulcers concluded that the application of silver dressings beneath compression did not improve ulcer healing. It must be noted here, however, that patients were randomized to receive either silver dressings or conventional non-adherent dressings without establishing whether their ulcer showed signs of infection or colonization, which is of course the primary reason for using silver dressings.

The benefits of using silver dressings, however, can be readily observed in clinical practice, as illustrated by the case studies presented here. These case studies used Atrauman<sup>®</sup> Ag dressing from Paul Hartmann Ltd, which has all the positive features of silver dressings, at a much reduced cost in comparison to its competitors (Table 3).

## Atrauman<sup>®</sup> Ag

Atrauman<sup>®</sup> Ag is a non-adherent primary contact wound layer, impregnated with silver. It consists of silvered polyamide interlaced yarn with a pore size of 1 mm which prevents granulation tissue from penetrating the dressing, resulting in minimal trauma and pain on removal. It allows the flow of exudate and air and provides a high level of conformability. The dressing is impregnated with neutral triglycerides, does not contain Vaseline or Paraffin, thus leaving the wound residue-free. The neutral triglycerides keep the wound margins soft and supple, avoiding scar tissue contraction.

## 'Touch and kill': Active antibacterial effect

When in contact with exudate Atrauman<sup>®</sup> Ag forms silver ions on its surface, killing bacteria on contact. The silver ions are kept within the dressing where they bind to and destroy bacteria. Atrauman<sup>®</sup> Ag is only bactericidal on direct contact with bacteria. Since the large majority of silver ions remain

**Table 3. Price comparison of Atrauman® Ag with other main wound dressings**

Catalogue code	HARTMANN code	Brand	Secondary description	Unit of issue	On-line catalogue price	Pro rata comparative price per dressing	Price per cm <sup>2</sup>	% saving if switched to Atrauman Ag
EKB039	499571	Atrauman Ag	5 x 5cm	10	£5.40	£0.54	£0.022	-
		Acticoat 7	5 x 5cm	5	£30.28	£6.06	£0.242	91%
		Acticoat	5 x 5cm	5	£16.93	£3.39	£0.135	84%
		Silvercel	5 x 5cm	10	£17.37	£1.74	£0.069	69%
		Actisorb Silver 220 with charcoal	6.5 x 9.5cm	10	£17.07	£1.71	£0.028	22%
		Aquacel Ag	5 x 5cm	10	£18.72	£1.87	£0.075	71%
EKB040	499573	Atrauman Ag	10 x 10cm	10	£12.82	£1.28	£0.013	-
		Acticoat 7	10 x 12.5cm	5	£84.96	£16.99	£0.136	91%
		Acticoat	10 x 10cm	12	£97.11	£8.09	£0.081	84%
		Urgotul SSD	10 x 12cm	25	£83.28	£3.33	£0.028	54%
		Silvercel	11 x 11cm	10	£41.74	£4.17	£0.034	63%
		Actisorb Silver 220 with charcoal	10.5 x 10.5cm	10	£26.00	£2.60	£0.024	46%
		Urgotul Silver	10 x 12cm	16	£56.56	£3.54	£0.029	56%
		Mepilex Ag	10 x 10cm	5	£31.00	£6.20	£0.062	79%
		Aquacel Ag	10 x 10cm	10	£44.76	£4.48	£0.045	71%
EKB041	499575	Atrauman Ag	10 x 20cm	10	£25.54	£2.55	£0.013	-
		Acticoat 7	15 x 15cm	5	£155.52	£31.10	£0.138	91%
		Acticoat	10 x 20cm	12	£151.73	£12.64	£0.063	80%
		Urgotul SSD	15 x 20cm	16	£158.31	£9.89	£0.033	61%
		Silvercel	10 x 20cm	5	£39.83	£7.97	£0.040	68%
		Actisorb Silver 220 with charcoal	10.5 x 19cm	10	£48.24	£4.82	£0.024	47%
		Urgotul Silver	15 x 20cm	16	£154.16	£9.64	£0.032	60%
		Mepilex Ag	10 x 20cm	5	£51.12	£10.22	£0.051	75%
		Aquacel Ag	15 x 15cm	5	£42.09	£8.42	£0.04	66%

Information taken from: NHS Supply Chain Online Catalogue Pricing (including VAT) - November 2010 (<https://my.supplychain.nhs.uk/catalogue> login needed)

within the dressing, cytotoxicity is kept to a minimum. Atrauman® Ag is not intended as a replacement for antibiotic therapy but as a complementary measure in the treatment of critically colonized or infected wounds.

As with any other primary dressing, Atrauman® Ag is used in combination with a secondary dressing, such as calcium alginates, foam dressings and absorbent wound dressing pads where the exudate, dead bacteria and endotoxins are absorbed into the secondary dressing. Depending on the amount of exudate, Atrauman® Ag can be left *in situ* for up to one week, with the secondary dressing being changed as necessary (see Case study 3). This makes Atrauman® Ag a cost-effective, safe and versatile product, which delivers all the positive clinical outcomes described by Lo et al (2008). These features make it an attractive alternative

antimicrobial dressing, particularly in the secondary care setting where the transmission of infection is a constant challenge to practitioners.

### Conclusion

Attempts to establish the efficacy of silver dressings in the treatment of infected or critically colonized wounds are not conclusive owing to the lack of good quality RCTs and poorly designed cost-effectiveness studies. In the absence of irrefutable evidence, practitioners need to be guided by their observations in clinical practice. Despite the negative reports of over-use and inappropriate use of silver dressings (Michaels et al, 2009), positive clinical outcomes have been achieved with the use of these products, such as a reduction in exudate and malodour, and improved wound margins

(Kapp and Smola, 2005; Ziegler et al, 2006). It is therefore suggested that clinicians should use their clinical judgment when considering silver dressing use, and Atrauman<sup>®</sup> Ag is an effective option that offers all of the benefits associated with antimicrobial dressings.

**BJCN**

#### Author's Note

This article was commissioned by Paul Hartmann Ltd and is to be viewed as an informed resource for those wishing to know more about their dressing ranges.

Figure 1 is reproduced with kind permission from A Kingsley.

- Adderley U (2010) Managing wound exudate and promoting healing. *British Journal of Community Nursing* (Suppl) **15**(3): S15-20
- Baker EA, Leaper DJ (2000) Proteinases, their inhibitors, and cytokine profiles in acute wound fluid. *Wound repair and regeneration* **8**(5): 392-8
- Bishop SM, Walker M, Rogers AA, Chen WY (2003) Importance of moisture balance at the wound-dressing interface. *Journal of Wound Care* **12**(4): 125-8
- Bolton L (2006) Are silver products safe and effective for chronic wound management? *Journal of Ostomy and Continence Nursing* **33**: 469-77
- Bowler PG, Davies BJ (1999) The microbiology of acute and chronic wounds. *Wounds* **11**(4): 72-8
- Bowler P, Duerden B, Armstrong D (2001) Wound microbiology and associated approaches to wound management. *Clinical microbiology reviews* **14**(2): 244-69
- Buchan IA, Andrews JK, Lang SM (1980) Clinical and laboratory investigation of the composition and properties of human skin wound exudate under semi-permeable dressings. *Burns* **7**: 326-34
- Collier M (2004) Recognition and management of infected wounds. World Wide Wounds: <http://www.worldwidewounds.com/2004/january/Collier/Management-of-Wound-infections.html> (Accessed 18 November 2010)
- Cooper R, Lawrence JC (1996) The isolation and identification of bacteria from wounds. *Journal of Wound Care* **5**(7): 335-40
- Cutting K, Harding K (1994) Criteria for identifying wound infection. *Journal of Wound Care* **3**(4): 198-201
- Dunn K, Edwards-Jones V (2004) The role of Acticoat Nano crystalline silver in the management of burns. *Burns* **30**: S1-9
- European Wound Management Association (2005) *Position Document: Identifying criteria for wound infection*. EWMA, London
- Frank C, Bayoumi I, Westendorp C (2005) Approach to infected skin ulcers. *Canadian family physician* **51**: 1352-9
- Gardner SE, Frantz RA, Doebbeling BN (2001) The validity of the clinical signs and symptoms used to identify localized chronic wound infection. *Wound repair and regeneration* **9**(3): 178-86
- Jorgensen B, Price P, Anderson KE et al (2005) The silver-releasing foam dressing, Contreet Foam, promotes faster healing of critically colonised venous ulcers: a randomised controlled trial. *International Wound Journal* **2**: 64-73
- Kapp H, Smola H (2005) Reduced cellular toxicity of a new silver-containing antimicrobial dressing and its clinical performance in non-healing wounds. *Primary Intention* **13**(4): S1-7
- Kingsley A (2003) The wound infection continuum and its application to clinical practice. *Ostomy Wound Management* **49**(S7a): 1-7
- Lawrence C (1985) The bacteriology of burns. *Journal of Hospital Acquired Infection* **6**: S3-17
- Lo SF, Hayter M, Chang CJ, Hu WY, Lee LL (2008) A systematic review of silver-releasing dressings in the management of infected chronic wounds. *Journal of Clinical Nursing* **17**: 1973-85
- MA Healthcare (2008) *Wound Care Handbook 2008-2009*. MA Healthcare, London
- Michaels JA, Campbell B, King B et al (2009) Randomized controlled trial and cost-effectiveness analysis of silver-donating antimicrobial dressings for venous leg ulcers (VULCAN trial). *British Journal of Surgery* **96**: 1147-56
- Moore K (1999) Cell biology of chronic wounds: the role of inflammation. *Journal of Wound Care* **8**(7): 345-8
- Murphy S, Denman S, Bennett RG, Greenough WB 3rd, Lindsay J, Zelesnick LB (1992) Methicillin-resistant *Staphylococcus aureus* colonization in a long-term care facility. *Journal of the American Geriatrics Society* **40**: 213-17
- National Prescribing Centre (2008) *Modern Wound Dressings: the Absence of Evidence*. NHS MeReC Extra, Liverpool: [http://www.npc.co.uk/eht/merrec/therap/wound/merrec\\_extra\\_no31.htm#MOD](http://www.npc.co.uk/eht/merrec/therap/wound/merrec_extra_no31.htm#MOD) (Accessed 18 November 2010)
- Nosocomial Infection National Surveillance Service (2002) *Surveillance of Surgical Site Infection in English Hospitals 1997-2002: a national surveillance and quality improvement programme*. Health Protection Agency, Communicable Disease Surveillance Centre, HCAI & AMR Department, London
- O'Meara SM, Cullum NA, Majid M, Sheldon TA (2001) Systematic review of antimicrobial agents used for chronic wounds. *British Journal of Surgery* **88**: 4-21
- Poon VKM, Burd A (2004) In vitro cytotoxicity of silver: implication for clinical wound care. *Burns* **30**: 140-7
- Siddiqui AR, Bernstein JM (2010) Chronic wound infection: Facts and controversies. *Clinics in Dermatology* **28**: 519-26
- Staiano-Coico L, Higgins PJ, Schwartz SB et al (2000) Wound fluids: a reflection of the state of healing. *Ostomy Wound Management* **46**(1A): S85-93
- Storm-Versloot MN, Vos CG, Ubbink DT, Vermeulen H (2010) Topical silver for preventing wound infection (Review). *Cochrane Database of Systematic Reviews* **3**: CD006478
- Thompson G, Stephen-Haynes J (2007) An overview of wound healing and exudate management. *British Journal of Community Nursing* **12**(12): S22-30
- Vermeulen H, van Hattem JM, Storm-Versloot MN, Ubbink DT (2009) Topical silver for treating infected wounds (Review). *Cochrane Database of Systematic Reviews* **1**: CD005486
- Vowden K, Vowden P (2003) Understanding exudate management and the role of exudate in the healing process. *British Journal of Community Nursing* **8**(11): S4-13
- Winter GD (1962) Formation of the scab and the rate of epithelialisation of superficial wounds in the skin of the young domestic pig. *Nature* **193**(4812): 293-4
- World Union of Wound Healing Societies (2008) *Principles of best practice: Wound infection in clinical practice: An international consensus*. WUWHS, London
- Ziegler K, Goerl R, Effing J, Ellerman J et al (2006) Reduced cellular toxicity of a new silver-containing antimicrobial dressing and clinical performance in non-healing wounds. *Skin Pharmacology and Physiology* **19**: 140-246

Copyright of British Journal of Community Nursing is the property of Mark Allen Publishing Ltd and its content may not be copied or emailed to multiple sites or posted to a listserv without the copyright holder's express written permission. However, users may print, download, or email articles for individual use.